



Protective and antioxidant effects of copper-nicotinate complex against glycerol-induced nephrotoxicity in rats

Ahmed Medhat Hegazy, Ahmed S. Hafez & Rania M. Eid

To cite this article: Ahmed Medhat Hegazy, Ahmed S. Hafez & Rania M. Eid (2018): Protective and antioxidant effects of copper-nicotinate complex against glycerol-induced nephrotoxicity in rats, Drug and Chemical Toxicology, DOI: [10.1080/01480545.2018.1481084](https://doi.org/10.1080/01480545.2018.1481084)

To link to this article: <https://doi.org/10.1080/01480545.2018.1481084>



Published online: 26 Jun 2018.



Submit your article to this journal [↗](#)

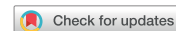

View related articles [↗](#)



View Crossmark data [↗](#)

RESEARCH ARTICLE



Protective and antioxidant effects of copper-nicotinate complex against glycerol-induced nephrotoxicity in rats

Ahmed Medhat Hegazy^a , Ahmed S. Hafez^b and Rania M. Eid^c

^aDepartment of Forensic Medicine and Toxicology, Faculty of Veterinary Medicine, Aswan University, Aswan, Egypt; ^bDepartment of Pharmacology, Faculty of Veterinary Medicine, Aswan University, Aswan, Egypt; ^cDepartment of Physiology, Faculty of Medicine, Aswan University, Aswan, Egypt

ABSTRACT

Copper-nicotinate complex (CNC) has antioxidant activities through scavenging of free radicals formed inside the body. CNC also has anti-tumor and anti-inflammatory activities. The current study was designed to determine the effect of glycerol on rat kidney function and oxidative stress as well as, the potential nephroprotective effects of CNC. Forty male Wistar rats were randomly allocated into four equal groups. The groups of rats were as follows: GI was kept under normal control conditions; GII was orally given CNC at a dose of 0.043 mg kg⁻¹ body weight (BW), three times/week for 4 weeks; GIII was administered glycerol (topical application) at a dose of 3.15 ml kg⁻¹ BW daily for 4 weeks; and GIV was given CNC and glycerol with the same dose and route. The results revealed that CNC improves the renal dysfunctions induced by glycerol by recovering the levels of urea and creatinine to normal, as well as through the antioxidant status manifested by the normalization of catalase, superoxide dismutase, reduced glutathione, and malondialdehyde levels. Moreover, by its effect as an anti-oxidant, CNC reduces the effect of glycerol on the kidney by decreasing the fibrosis, degenerative changes and necrotic changes in the renal tubules. In conclusion, CNC could alleviate the side effects that might be caused by glycerol.

ARTICLE HISTORY

Received 2 February 2018
Revised 19 May 2018
Accepted 22 May 2018

KEYWORDS

Rats; copper-nicotinate complex; glycerol; nephroprotective; antioxidant

Introduction

The kidney is one of the major organs involved in whole-body homeostasis, with its major functions being the excretion of waste metabolites, blood pressure regulation, metabolism of lipids, secretion and degradation of hormones and production and utilization of systemic glucose (Gai *et al.* 2014). The incidence of acute kidney injury (AKI) is 4085 per million populations per year in developed nations (Ali *et al.* 2007, Hsu *et al.* 2007). AKI is induced by ischaemia, nephrotoxins and toxic agents such as mercuric chloride, aminoglycosides, cisplatin, cyclosporine and glycerol (Zager 1997) and (Baliga *et al.* 1999). Studies have shown that free radical formation and direct tubular toxicity might play important roles in the development of nephropathy (Wong *et al.* 2012), a probable pathophysiological mechanism.

Glycerol is used in cosmetics as a denaturant, fragrance ingredient, hair conditioning agent, humectant, oral care agent, oral health care drug, skin protectant, skin conditioning agent and viscosity decreasing agent, in addition to being present in tobacco (Nikitakis and Breslawec 2013). The mechanism of glycerol-induced nephrotoxicity is not completely known. However, studies have implicated that the peroxidation of lipids leads to the spread of free radical reactions; thus, lipid peroxidation (LPO) is considered a biochemical oxidative stress mechanism (Ramar *et al.* 2012). Abnormal

production of such molecules may damage macromolecules and induce cellular injury as well as necrosis (Baliga *et al.* 1998, Parlakpınar *et al.* 2003). Accordingly, the administration of compounds with antioxidant activity has been successfully used to prevent glycerol-induced nephrotoxicity (Cuzzocrea *et al.* 2002, Karahan *et al.* 2005).

Copper (Cu) is required for the function of several co-enzymes essential for different physiological functions and integrated into essential biochemical pathways (Linder 1991, Vančo *et al.* 2008). Copper complexes can modulate Cu homeostasis in different tissues, resulting in protective effects against several degenerative diseases. Copper-nicotinate complex (CNC) [CuCl (HNA)₂] was found to exhibit various bioactivities such as anti-tumour and anti-inflammatory activities (Belicchi *et al.* 2002). The complex has a cytoprotective effect and superoxide dismutase (SOD)-mimicking activity. It has also been found to prevent gastric congestion, prevent capillary damage, stimulate blood flow and reduce LPO and oxidative stress markers (El-Saadani *et al.* 1993). Additionally, the complex has significant curative effects in rats with induced rheumatoid arthritis and nonalcoholic fatty liver (Salama *et al.* 2007). Copper deficiency has emerged as a factor in the development of nonalcoholic fatty-liver disease (Aigner *et al.* 2010, Lampón and Tutor 2010) and ischaemic heart disease (Jalili *et al.* 1996).

Concerning the complex pathophysiological mechanism of renal disease, this study aimed to evaluate the protective effect of the CNC on the kidney functions of Wister rats exposed to topical application of glycerol.

Materials and methods

The Institutional Animal Ethics Committee approved all experimental protocols (No. 43 at 10 April 2016) conducted at Benha University, Egypt.

Chemicals

Glycerol solution was purchased from Memphis Co., Egypt. The solution was dissolved in distilled water (75%) and administered to 30% of the body surface of rats after shaving of the hair of the back daily for 4 weeks at a dose of 3.15 ml kg^{-1} body weight (BW) (Dataset 2008).

Copper-nicotinate complex

The copper-nicotinate complex was obtained as a gift from Professor Dr Ahmed Yassen Nassar, Professor of Biochemistry, Faculty of Science, Asuite University. The complex was prepared by adding a suspension of copper (I) chloride in aqueous alcohol, to nicotinic acid dissolved in aqueous alcohol to obtain a reactant solution, from which develops a clear red-dish precipitate of the nicotinic acid copper (I) chloride complex. The final mixture was allowed to stand over several hours until the crystalline precipitate was formed. The precipitate was filtered utilizing a pump and washed with ascorbic acid solution in alcohol, the solution comprising 70–90% ascorbic acid, further washings with ethanol 70–99%, acetone and then dried under vacuum (Ibraheim, 2013). It was administered to rats at a dose of 0.043 mg kg^{-1} BW, three times per week continuously for 4 weeks, according to a previous method (Musa *et al.* 1987).

Experimental animals

Five-week-old male Wistar rats (120–140 g) were obtained from the Animal House, National Cancer Institute, Cairo, Egypt. All animals were housed in clean cages and given a balanced diet and water *ad libitum*. Their environmental condition was controlled in terms of light (12-h light–dark cycle starting at 8:00 a.m.) and room temperature ($23 \pm 3^\circ \text{C}$). Clinical signs were recorded for all groups during the period of the experiment. At the end of the fourth week of the experiment, blood samples were collected from the retro-orbital venous plexus of each rat. Each blood sample was placed in a plain centrifuge tube for separation of the serum. The serum samples were stored at -20°C for further biochemical analysis. At the end of the fourth week of the experiment, the rats were euthanized, and two portions of kidney tissue specimens were collected from five rats in each group. The first portion of kidney specimen was stored at -70°C for evaluation of the oxidative/antioxidant parameters. The second portion of kidney specimens was collected

immediately after sacrifice and fixed in 10% formal saline for histopathological examinations.

Experimental design

Forty male Wistar rats were randomly allocated into four groups (10 rats per group). The first group (GI) was kept as the control. The second group (GII) was given CNC at a dose of 0.043 mg kg^{-1} BW orally by a stomach tube three times per week continuously for 4 weeks. The third group (GIII) was given glycerol (topical application) dissolved in distilled water (75%) and administered daily to 30% of the body surface of rats after clipping the hair of the back for 4 weeks continuously at a dose of 3.15 ml kg^{-1} BW. The fourth group (GIV) was given CNC (0.043 mg kg^{-1} BW) orally by stomach tube three times per week continuously for 4 weeks and 75% glycerol in distilled water at a dose of 3.15 ml kg^{-1} BW via daily topical application on the back after clipping the hair continuously for 4 weeks. Clinical signs were recorded for all groups during the period of the experiment. Blood for serum samples was collected from the retro-orbital venous plexus, and kidney specimens were collected from all rats in each group at the end of the fourth week of the experiment for evaluation of kidney function, oxidative parameters, and histopathological changes.

Preparation of kidney homogenate

One gram of kidney tissue was collected from each rat of the different groups at the end of the fourth week of the experiment. The kidney tissue was washed in ice-cold 0.9% NaCl and homogenized in ice-cold 1.15% potassium chloride solution in 50 mmol potassium phosphate buffer solution (pH 7.4) to yield a 10% kidney homogenate solution (W/V). Homogenization was performed using a sonicator (4710 Ultrasonics Homogenizer, Cole-Parmer Instrument Co., USA). The homogenate was centrifuged at 4000 rpm for 5 min at 4°C . The supernatant was collected and used for determination of the concentration of reduced glutathione (GSH), the activities of SOD and catalase (CAT) and LPO by-products.

Assay methods

Determination of kidney function tests

Colorimetric determination of the urea concentration in serum was performed according to Patton and Crouch (1977). Kinetic determination of creatinine in serum was also performed according to Tietz (1995).

Oxidant/antioxidant markers in kidney homogenate

The activity of CAT in kidney homogenate was performed according to Luck (1963). The enzyme activity was determined based on its ability to decompose H_2O_2 and expressed as IU mg^{-1} protein. The activity of SOD in the kidney homogenate was determined according to Misra and Fridovich (1972). The enzyme activity was determined according to its ability to inhibit the autoxidation of epinephrine in alkaline

Table 1. Effect of CNC against glycerol effects on kidney function in different groups of the experiment after 4 weeks of treatment (mean \pm SE, $n = 10$).

Groups Parameters	GI (Normal control)	GII (CNC only)	GIII Glycerol	GIV CNC and glycerol
Urea (mg/dl)	26.178 \pm 2.134 ^b	28.012 \pm 0.995 ^b	43.826 \pm 1.643 ^a	31.564 \pm 2.646 ^b
Creatinine (mg/dl)	0.450 \pm 0.032 ^b	0.452 \pm 0.039 ^b	0.576 \pm 0.010 ^a	0.398 \pm 0.038 ^b

Means with different superscripts in the same row are significantly different at $p < 0.05$.

medium. The activity of SOD was expressed as IU mg^{-1} protein.

The reduced GSH content in the kidney homogenate was determined according to Ellman (1959). The reduced chromogen was directly proportional to the GSH concentration and its absorbance was measured at 405 nm. The concentrations of GSH were expressed as $\mu\text{mol mg}^{-1}$ protein.

LPO by-products in the kidney tissue homogenate were analyzed according to Ohkawa *et al.* (1979) based on the reaction of thiobarbituric acid with malondialdehyde in acidic media at 95 °C for 45 min to form thiobarbituric acid-reactive substances. The resulting pink-coloured reaction product was extracted with *n*-butanol, and the absorbance was determined at 535 nm. The level of lipid peroxides was expressed as nmol mg^{-1} protein.

The total protein concentration in the kidney homogenate was measured according to Miller (1959) using bovine serum albumin as a standard. A spectrophotometer (Model, JASCO 7800, UV/VIS, Japan) was used for the measurement.

Histopathological examinations

Tissue samples were taken from the kidneys of rats in the different groups and fixed in neutral buffered formalin (10%). Washing was performed using tap water; then, serial dilutions of alcohol (methyl, ethyl and absolute ethyl) were used for dehydration. Specimens were cleared in xylene and embedded in paraffin at 56 °C in a hot air oven for 24 h. Paraffin bees-wax tissue blocks were prepared for sectioning at 4- μm thickness. The obtained tissue sections were collected on glass slides, deparaffinized and stained with haematoxylin and eosin (H&E) stains (Bancroft and Cook 1994) for histopathological examination through light microscopy.

Statistical analysis

Statistical analysis was performed using the statistical software package (SPSS) for Windows (Version 20.0; SPSS Inc., Chicago, IL). The significance of differences between more than two groups was evaluated by one-way analysis of variance followed by Duncan's multiple range test (Snedecor and Cochran 1989). Differences were considered significant at the $p < 0.05$ level. The data were expressed as the mean \pm SE.

Results

During the period of the experiment, no mortality was observed in any of the experimental groups.

Serum urea and creatinine

The levels of urea and creatinine significantly increased in the glycerol-treated group to 43.826 \pm 1.643 and 0.576 \pm 0.010 mg/dl, respectively compared with the three other experimental groups after the fourth week of treatment. On the other hand, the group co-treated with glycerol and copper showed mitigation of urea and creatinine levels to 31.564 \pm 2.646 and 0.398 \pm 0.038 mg/dl, respectively after the fourth week of the experiment (Table 1).

Changes in the kidney antioxidant parameters

The activities of CAT, SOD and GSH in the kidney tissue of the glycerol-treated group decreased significantly to 1.064 \pm 0.130 IU mg^{-1} protein, 0.064 \pm 0.013 IU mg^{-1} protein, and 0.144 \pm 0.021 $\mu\text{mol mg}^{-1}$ protein respectively when compared with the three other experimental groups, while the group co-treated with glycerol and copper showed alleviation of these enzymatic activities to 3.092 \pm 0.386, 0.541 \pm 0.063 and 0.339 \pm 0.031 $\mu\text{mol mg}^{-1}$ protein, respectively after the fourth week of the experiment. Likewise, the levels of MDA, a marker of LPO in kidney tissue, were significantly increased in the glycerol-treated to 1.039 \pm 0.044 nmol mg^{-1} protein when compared with the three other experimental groups, while the group co-treated with glycerol and copper showed mitigation of MDA levels to 0.323 \pm 0.075 nmol mg^{-1} protein after the fourth week of the experiment (Table 2).

Histopathological examination of kidney tissue

Histopathological examinations were conducted after 4 weeks of the experiment.

Kidneys of the control group (GI) showed normal histological structures of the glomeruli and renal tubules. Moreover, there was no histopathological alteration observed in the kidneys of rats (GII) that received the CNC (Figure 1(a)). On the other hand, the kidneys of rats that received glycerol (GIII) showed renal casting, necrotic changes in the renal medulla and periglandular fibrosis with infiltration of inflammatory cells associated with degenerative changes in the renal tubules (Figure 1(b,c)). However, kidneys of rats that received both glycerol and CNC (GIV) appeared normal with some degeneration in some renal tubules (Figure 1(d)).

Discussion

This work was designated to investigate the efficacy of CNC on maintaining the kidney functions of Wister rats exposed to topical application of glycerol.

The incidence and prevalence of chronic renal failure (CRF) is on the increase in developed countries, producing a very

Table 2. Effect of CNC against glycerol effects on oxidative/antioxidative parameters in the kidney homogenates of different groups of experiment after 4 weeks of treatment (mean \pm SE, $n = 10$).

Groups Parameters	GI Normal control	GII CNC only	GIII Glycerol	GIV CNC and glycerol
CAT (IU mg ⁻¹ protein)	4.216 \pm 0.473 ^a	4.487 \pm 0.442 ^a	1.064 \pm 0.130 ^b	3.092 \pm 0.386 ^a
SOD (IU mg ⁻¹ protein)	0.551 \pm 0.041 ^a	0.589 \pm 0.025 ^a	0.064 \pm 0.013 ^b	0.541 \pm 0.063 ^a
GSH reduced (μ mol mg ⁻¹ protein)	0.403 \pm 0.016 ^a	0.388 \pm 0.013 ^a	0.144 \pm 0.021 ^b	0.339 \pm 0.031 ^a
Malondialdehyde (nmol mg ⁻¹ protein)	0.229 \pm 0.070 ^b	0.283 \pm 0.061 ^b	1.039 \pm 0.044 ^a	0.323 \pm 0.075 ^b

Means with different superscripts in the same row are significantly different at $p < 0.05$.

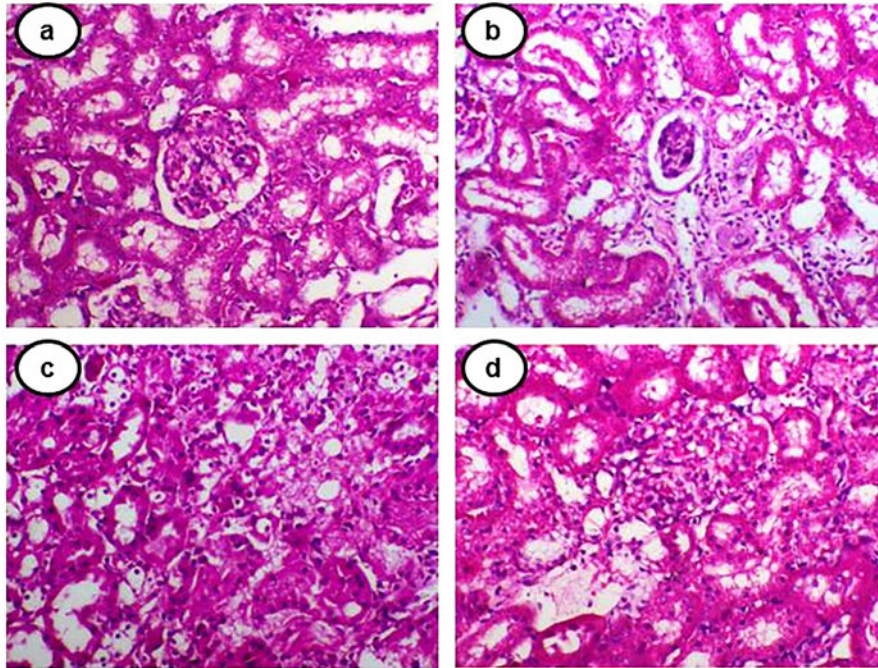


Figure 1. Kidney sections of rats from different experimental groups. (a) The negative control group (GI) and (GII) received CNC orally and showed a normal histological structure of the kidney with no abnormalities. (b,c) show kidneys of Group III rats that received glycerol (topical application). (b) Shows periglandular fibrosis with infiltration of inflammatory cells associated with degenerative changes in renal tubules, and (c) shows necrotic changes in the renal medulla. (d) Group IV received CNC and glycerol and showed normal kidneys with some degeneration in some renal tubules (H&E $\times 200$).

expensive and rising demand on health-care systems already burdened by scarcity of resources (James *et al.* 2010, Nugent *et al.* 2011). The disease is progressive in nature and requires involved and frequently expensive management. CRF causes serious complications such as diabetes, stroke, cardiovascular disease and other diseases and has no satisfactory treatment (Smart and Titus 2011).

In this study, the glycerol treated rats showed no apparent clinical signs of toxicity. Additionally, there was no significant effect on the BWs of these rats, giving no indication of stress on the rats due to the given doses of glycerol.

In this study, there was a significant increase in the urea and creatinine levels observed, which indicates kidney injury. The elevation in urea was almost two times that of the value measured in control groups at the end of 4 weeks of administration of glycerol. Similarly, the elevation in creatinine was statistically significant compared with that of the control groups after the fourth weeks of receiving glycerol. The elevated serum levels of urea and creatinine may have been due to impaired renal function, which is characterized by a rapid reduction in the ability of the kidney to eliminate waste products, resulting in accumulation of the normal end products of nitrogen metabolism either from the diet or normal tissue catabolism and a corresponding rise of urea and creatinine (El-Kott *et al.* 2015). A similar increase in urea and

creatinine levels caused by glycerol has been reported in a previous study (Konda *et al.*, 2016, Kunak *et al.*, 2016). Glycerol is toxic to rat kidney cells, causing injury of the renal tubules and an inflammatory response in the kidney (Komada *et al.*, 2016). Glycerol-induced renal injury produces oxidative stress and catalytic effects of redox-active iron. The main mechanisms of glycerol-induced AKI in the rat model are renal vasoconstriction, intraluminal cast formation, and direct haeme-iron-induced cytotoxicity (Bosch *et al.* 2009). Iron (Fe) has been implicated to play an important role in myoglobinuric AKI (Baliga *et al.*, 1996). Haeme-Fe causes proximal tubular LPO and cytotoxicity without invoking release of free iron, and this process is due to redox cycling of the heme-Fe complex from ferrous to ferric and ferryl oxidation states (Estaphan *et al.* 2015).

There was a significant decrease in the levels of urea and creatinine when rats were co-treated with glycerol and CNC. This result might have been due to the nephroprotective activity of the CNC. A previous study reported that the kidney gained a considerable amount of the administered copper complex, and that filtered copper may undergo ligand exchange in the distal tubules, which accounts for the participation of the kidney in copper conservation (Sorenson 2012).

These results concurred with the improvement in histopathological features of the kidneys of CNC-treated rats when

compared with the kidneys of glycerol-treated rats, which showed periglandular fibrosis with infiltration of inflammatory cells associated with degenerative changes in the renal tubules, in addition to necrotic changes in the renal medulla. These findings coincided with those of a previous study (El-Kott *et al.* 2015). Glycerol and CNC treatment resulted in normal kidneys with some degeneration in some renal tubules.

In this study, there was an increase in LPO indicated by an elevation in the MDA level and a decrease in the CAT, SOD and GSH activities observed in rats treated with glycerol after the fourth week of treatment. This effect might have been due to the peroxidation of membrane lipids and injury to cellular components (Abassi *et al.* 1998, Singh *et al.* 2003). Reduction of LPO (MDA) levels and increases in the CAT and SOD activities were observed when rats were co-treated with glycerol and CNC. CNC is a rich source of antioxidant activity (Tuorkey and Abdul-Aziz 2009), and its detoxifying action is attributed to its scavenging activity of free radicals (Nassar *et al.* 2012). CNC exhibits SOD-mimicking activity (Suksrichavalit *et al.* 2008). The complex has potential to decrease inflammation, exhibit antioxidant properties and control LPO (Verstraeten *et al.* 1997), in addition to acting as an anti-inflammatory agent in the treatment of oxidative stress- and apoptosis-associated neurodegenerative diseases (Qusti *et al.* 2018).

Conclusions

In this work, we provide information about the role of CNC as an antioxidant agent, which could alleviate the side effects that might be caused by glycerol application by reducing ROS production, maintaining the antioxidant potential, and significantly reducing renal damage.

Disclosure statement

No potential conflict of interest was reported by the authors.

ORCID

Ahmed Medhat Hegazy  <http://orcid.org/0000-0001-8606-5937>

References

- Abassi, Z.A., Hoffman, A., and Better, O.S., 1998. Acute renal failure complicating muscle crush injury. *Proceedings of the Seminars in Nephrology*, 18, 558–565.
- Aigner, E., *et al.*, 2010. A role for low hepatic copper concentrations in nonalcoholic fatty liver disease. *The American Journal of Gastroenterology*, 105 (9), 1911–1985.
- Ali, T., *et al.*, 2007. Incidence and outcomes in acute kidney injury: a comprehensive population-based study. *Journal of the American Society of Nephrology*, 18 (4), 1292–1298.
- Baliga, R., *et al.*, 1999. Oxidant mechanisms in toxic acute renal failure. *Drug Metabolism Reviews*, 31 (4), 971–997.
- Baliga, R., *et al.*, 1996. Evidence for cytochrome P-450 as a source of catalytic iron in myoglobinuric acute renal failure. *Kidney International*, 49 (2), 362–369.
- Baliga, R., *et al.*, 1998. In vitro and in vivo evidence suggesting a role for iron in cisplatin-induced nephrotoxicity. *Kidney International*, 53 (2), 394–401.
- Bancroft, J.D. and Cook, H.C., 1994. *Manual of histological techniques and their diagnostic application*. London: Churchill Livingstone.
- Belicchi, F.M., *et al.*, 2002. Synthesis, characterization and biological activity of two new polymeric copper (II) complexes with alpha-ketoglutaric acid thiosemicarbazone. *Journal of Inorganic Biochemistry*, 89 (1–2), 36–44.
- Bosch, X., Poch, E., and Grau, J.M., 2009. Rhabdomyolysis and acute kidney injury. *The New England Journal of Medicine*, 361 (1), 62–72.
- Cuzzocrea, S., *et al.*, 2002. A role for superoxide in gentamicin-mediated nephropathy in rats. *European Journal of Pharmacology*, 450 (1), 67–76.
- Dataset, I., 2008. European Commission European Chemical Bureau. Available from: http://ecb.jrc.it/Documents/ExistingChemicals/UCLID/DATA_SHEETS/10124433.pdf
- El-Kott, A.F., Al-Bakry, K.A., and Eltantawy, W.A., 2015. Preventive and curative effects of Zingiber officinale extract against histopathological and Ki-67 immunohistochemical changes of glycerol-induced acute renal failure in rat. *Journal of Medical Sciences*, 15 (1), 25.
- El-Saadani, M.A., *et al.*, 1993. The protective effect of copper complexes against gastric mucosal ulcer in rats. *Biochemical Pharmacology*, 46 (6), 1011–1018.
- Ellman, G.L., 1959. Tissue sulfhydryl groups. *Archives of Biochemistry and Biophysics*, 82 (1), 70–77.
- Estaphan, S., *et al.*, 2015. A study on the effect of cimetidine and l-carnitine on myoglobinuric acute kidney injury in male rats. *Injury*, 46 (7), 1223–1230.
- Gai, Z., *et al.*, 2014. Effect of chronic renal failure on the hepatic, intestinal, and renal expression of bile acid transporters. *American Journal of Physiology-Renal Physiology*, 306 (1), 130–137.
- Hsu, C.-Y., *et al.*, 2007. Community-based incidence of acute renal failure. *Kidney International*, 72 (2), 208–212.
- Ibraheim, S.F.H.A., 2013. *Method for preparation of nicotinic acid copper chloride complex, and its pharmaceutical uses*. Google Patents Pub.No. US 2013/0184247 A1.
- Jalili, T., Medeiros, D.M., and Wildman, R.E., 1996. Aspects of cardiomyopathy are exacerbated by elevated dietary fat in copper-restricted rats. *The Journal of Nutrition*, 126 (4), 807.
- James, M.T., Hemmelgarn, B.R., and Tonelli, M., 2010. Early recognition and prevention of chronic kidney disease. *Lancet (London, England)*, 375 (9722), 1296–1309.
- Karahan, I., *et al.*, 2005. Protective effect of lycopene on gentamicin-induced oxidative stress and nephrotoxicity in rats. *Toxicology*, 215 (3), 198–204.
- Komada, T., *et al.*, 2015. Role of NLRP3 inflammasomes for rhabdomyolysis-induced acute kidney injury. *Scientific Reports*, 5 (1), 10901.
- Konda, V.R., *et al.*, 2016. Nephroprotective effect of ethanolic extract of Azima tetracantha root in glycerol induced acute renal failure in Wistar albino rats. *Journal of Traditional and Complementary Medicine*, 6 (4), 347–354.
- Kunak, C.S., *et al.*, 2016. Nephroprotective potential of carnitine against glycerol and contrast-induced kidney injury in rats through modulation of oxidative stress, proinflammatory cytokines, and apoptosis. *The British Journal of Radiology*, 89 (1058), 20140724.
- Lampón, N. and Tutor, J.C., 2010. Effect of valproic acid treatment on copper availability in adult epileptic patients. *Clinical Biochemistry*, 43 (13–14), 1074–1078.
- Linder, M.C., 1991. Introduction and overview of copper as an element essential for life. *Biochemistry of Copper*. Plenum, NY: Springer, 1–13.
- Luck, H., 1963. A spectrophotometric method for the estimation of catalase. In: H.U. Bergmeyer, Ed. *Methods of enzymatic analysis*. New York: Academic press, 886–887.
- Miller, G.L., 1959. Protein determination of large numbers of samples. *Analytical Chemistry*, 31 (5), 964–964.
- Misra, H.P. and Fridovich, I., 1972. The role of superoxide anion in the autoxidation of epinephrine and a simple assay for superoxide dismutase. *Journal of Biological Chemistry*, 247, 3170–3175.
- Musa, S., *et al.*, 1987. Copper (I)-nicotinic acid complex: an immunopotentiator in chickens vaccinated against newcastle disease. In: Sorenson,

- J.R.J., ed. *Biology of Copper Complexes*. New Jersey: Humana Press, Springer, 343–350.
- Nassar, M.A., et al., 2012. Time-dependent morphological and biochemical changes following cutaneous thermal burn injury and their modulation by copper nicotinate complex: an animal model. *Ultrastructural Pathology*, 36 (5), 343–355.
- Nikitakis, J. and Breslawec, H.P., 2013. *International cosmetic ingredient dictionary and handbook*. 15th ed. Washington, DC: Personal Care Products Council.
- Nugent, R.A., et al., 2011. The burden of chronic kidney disease on developing nations: a 21st century challenge in global health. *Nephron Clinical Practice*, 118 (3), c269–c277.
- Ohkawa, H., Ohishi, N. and Yagi, K., 1979. Assay for lipid peroxides in animal tissues by thiobarbituric acid reaction. *Analytical Biochemistry*, 95 (2), 351–358.
- Parlakpınar, H., et al., 2003. Amikacin-induced acute renal injury in rats: protective role of melatonin. *Journal of Pineal Research*, 35 (2), 85–90.
- Patton, C.J. and Crouch, S., 1977. Spectrophotometric and kinetics investigation of the Berthelot reaction for the determination of ammonia. *Analytical Chemistry*, 49 (3), 464–469.
- Qusti, S.Y., et al., 2018. Role of combined administration of copper-nicotinic acid complex and coenzyme Q10 against aluminium chloride-induced oxidative stress in rat brain. *Pharmacophore*, 9, 17–27.
- Ramar, M., et al., 2012. Protective effect of ferulic acid and resveratrol against alloxan-induced diabetes in mice. *European Journal of Pharmacology*, 690 (1–3), 226–235.
- Salama, R.H., et al., 2007. A novel therapeutic drug (copper nicotinic acid complex) for non-alcoholic fatty liver. *Liver International*, 27 (4), 454–464.
- Singh, D., Chander, V., and Chopra, K., 2003. Carvedilol, an antihypertensive drug with antioxidant properties, protects against glycerol-induced acute renal failure. *American Journal of Nephrology*, 23 (6), 415–421.
- Smart, N.A. and Titus, T.T., 2011. Outcomes of early versus late nephrology referral in chronic kidney disease: a systematic review. *The American Journal of Medicine*, 124 (11), 1073–1080. e1072.
- Snedecor, G. and Cochran, W., 1989. Analysis of variance: the random effects model. In: H. Sahai and M.M. Ojeda, eds. *Statistical Methods*. 8th ed., Vol. 1. Ames, IA: Iowa State University Press, 237–252.
- Sorenson, J.R., 2012. *Biology of copper complexes*. Clifton, NJ: Springer Science & Business Media.
- Suksrichavalit, T., et al., 2008. Copper complexes of nicotinic-aromatic carboxylic acids as superoxide dismutase mimetics. *Molecules*, 13 (12), 3040–3056.
- Tietz, N.W., 1995. *Clinical guide to laboratory tests*. Philadelphia, PA: WB Saunders Co.
- Tuorkey, M.J.F.-A. and Abdul-Aziz, K.K., 2009. A pioneer study on the anti-ulcer activities of copper nicotinate complex [CuCl (HNA) 2] in experimental gastric ulcer induced by aspirin-pylorus ligation model (Shay model). *Biomedicine and Pharmacotherapy*, 63 (3), 194–201.
- Vančo, J., et al., 2008. Synthesis, structural characterization, antiradical and antidiabetic activities of copper (II) and zinc (II) Schiff base complexes derived from salicylaldehyde and β -alanine. *Journal of Inorganic Biochemistry*, 102 (4), 595–605.
- Verstraeten, S.V., et al., 1997. Effect of trivalent metal ions on phase separation and membrane lipid packing: role in lipid peroxidation. *Archives of Biochemistry and Biophysics*, 338 (1), 121–127.
- Wong, P.C.Y., et al., 2012. Pathophysiology of contrast-induced nephropathy. *International Journal of Cardiology*, 158 (2), 186–192.
- Zager, R.A., 1997. Pathogenetic mechanisms in nephrotoxic acute renal failure. *Seminars in Nephrology*, 17 (1), 3–14.